

GYNECOLOGIC PATHOLOGY REPORT

LIPATH, PC www.lipath.com

40 Meeting House Lane, Suite 3, Southampton, NY 11968

Toll Free 1.888.4LIPATH (1.888.454.7284); Phone 631.726.8264; Fax 631.726.8262



PATIENT INFORMATION	PHYSICIAN INFORMATION	SPECIMEN INFORMATION
SMITH JONES AGE/SEX: 51Y/F D.O.B: 09/07/1950 PATIENT ID: 000-99-9999	MARY JONES, MD	SURGICAL #: S08-02001 MEDICAL REC #: 0315961 ACCOUNT #: 409514 CHART #: 12465 LOCATION: ASC
DATE COLLECTED: 2/20/2008	DATE RECEIVED: 2/20/2008	DATE REPORTED: 2/21/2008

CLINICAL INFORMATION:

Rule out dysplasia.

DIAGNOSIS:

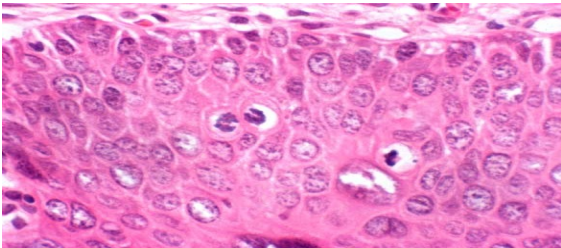
A. Uterus, cervix, 12 O'clock, biopsy:

- **HIGH GRADE SQUAMOUS INTRAEPITHELIAL LESION (CIN-3)**

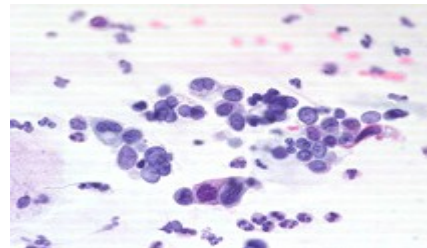
B. Uterus, endocervix, curetting:

- **BENIGN ENDOCERVICAL TISSUE**

BIOPSY



PREVIOUS CYTOLOGY WITH HGSIL



MACROSCOPIC DESCRIPTION:

Specimen designated "cervical bx at 12 o'clock" received in formalin and labeled with the patient's name, consists of 2 pieces of white mucosal tissue measuring up to 0.3x0.2x0.1 cm in greatest dimension. Entirely submitted in 1 cassette.

Specimen designated "ECC" received in formalin and labeled with the patient's name, consists of mucus measuring up to 0.2x0.1x0.1 cm in greatest aggregate dimension. Entirely submitted in 1 cassette. (AT/at)

PATHOLOGIST:

Ali Tamsen, MD, FACP / Electronically Signed