

UROPATHOLOGY REPORT

LIPATH, PC www.lipath.com

40 Meeting House Lane, Suite 3, Southampton, NY 11968

Toll Free 1.888.4LIPATH (1.888.454.7284); Phone 631.726.8264; Fax 631.726.8262



PATIENT INFORMATION	PHYSICIAN INFORMATION	SPECIMEN INFORMATION	
JANE DOE AGE/SEX: 51Y/F D.O.B: 09/07/1950 PATIENT ID: 000-99-9999	MICHAEL JONES, MD	SURGICAL #:	S02-02010
		MEDICAL REC #:	0315961
		ACCOUNT #:	409514
		CHART #:	12465
		LOCATION:	ASC
DATE COLLECTED: 6/20/2002	DATE RECEIVED: 6/20/2002	DATE REPORTED:	6/21/2009

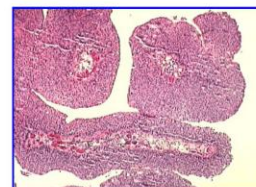
CLINICAL INFORMATION:

Hematuria.

DIAGNOSIS

Bladder, posterior wall, biopsy:

- LOW GRADE PAPILLARY UROTHELIAL CARCINOMA
- NO LAMINA PROPRIA INVASION IS IDENTIFIED
- NO MUSCLE LAYER INVASION IDENTIFIED



THE WHO/ISUP CONSENSUS CLASSIFICATION OF UROTHELIAL NEOPLASMS

Normal

Normal*

Hyperplasia

Flat hyperplasia

Papillary hyperplasia

Flat lesions with atypia

Reactive (inflammatory) atypia

Atypia of unknown significance

Dysplasia (low-grade intraurothelial neoplasia)

Carcinoma in situ (high-grade intraurothelial neoplasia)+

Papillary neoplasms

Papilloma

Inverted papilloma

Papillary neoplasm of low malignant potential

Papillary carcinoma, low-grade

Papillary carcinoma, high-grade++

Invasive neoplasms

Lamina propria invasion

Muscularis propria (detrusor muscle) invasion

*May include cases formerly diagnosed as "mild dysplasia." +Includes cases with "severe dysplasia."

++ Option exists to add comment as to the presence of marked anaplasia. **Reference:** Am J Surg Pathol, Vol. 22. No. 12, 1998

MACROSCOPIC DESCRIPTION:

Specimen designated as "bladder wall biopsy-posterior" received in formalin and labeled with patient's name, consists of three pieces of soft pink tissue up to 0.5x0.2x0.2 cm in greatest dimension. Entirely submitted in one cassette.

PATHOLOGIST: Ali Tamsen, MD / Electronically Signed

BILLING CODES

CPT 88305

ICD9 188.9